

## Magnetic Resonance Imaging Evaluation of Endometrial Carcinoma: A Retrospective Case Series

Dr. Snehsiddha<sup>1</sup>, Dr. Bhawana Sonawane<sup>2</sup>, Dr. Anagha Deshpande<sup>3</sup>, Dr. Charu<sup>4</sup>

<sup>1</sup>Junior Resident (JR1), Department of Radio diagnosis, IGGMC Nagpur.

<sup>2,3</sup>Professor and Head, Department of Radio diagnosis, IGGMC Nagpur.

<sup>4</sup>Junior Resident (JR3), Department of Radio diagnosis, IGGMC Nagpur.



### Article History

Received: 16.03.2026

Accepted: 20.04.2026

Published: 02.05.2026

Corresponding Author:  
Dr Snehsiddha

**Abstract: Background:** Endometrial carcinoma is the most common gynecologic malignancy in women and frequently presents with postmenopausal bleeding. Accurate preoperative staging is essential for determining appropriate treatment and predicting prognosis. Magnetic resonance imaging (MRI) with its superior soft-tissue contrast has emerged as the modality of choice for preoperative evaluation.

**Aim:** To evaluate the role of MRI in preoperative assessment and FIGO staging of endometrial carcinoma and to correlate imaging findings with histopathological reports.

**Methods:** A retrospective observational study was conducted at the Department of Radio diagnosis, IGGMCH Nagpur from November 2020 to December 2025, including 16 patients with histologically confirmed or imaging-suspected endometrial carcinoma who underwent contrast-enhanced MRI of the pelvis. MRI findings were assessed for tumor size, depth of myometrial invasion, cervical stromal involvement, parametrial extension, adnexal spread, pelvic/para-aortic lymphadenopathy and FIGO staging.

**Results:** The mean patient age was 58 years (range 35–65 years). Postmenopausal bleeding was the predominant presenting symptom. MRI detected an endometrial mass in all 16 cases. Superficial myometrial invasion (<50%) was noted in 37.5% (n=6) and deep invasion (≥50%) in 31.25% (n=5) of cases. Cervical stromal involvement was identified in 31.25% (n=5). FIGO staging distribution: Stage IA – 31.25%, Stage IB – 18.75%, Stage II – 25%, Stage III – 12.5%, Stage IVB – 12.5%.

**Conclusion:** MRI is a reliable and indispensable imaging modality for preoperative staging of endometrial carcinoma. It accurately delineates tumor extent, depth of myometrial invasion, cervical stromal involvement and extra uterine spread, thereby guiding surgical planning and adjuvant therapy decisions.

**Keywords:** Endometrial carcinoma; MRI pelvis; FIGO staging; myometrial invasion; cervical stromal involvement; diffusion-weighted imaging.

### Cite this Article

Snehsiddha, B. Sonawane, A. Deshpande, Charu, (2026) Magnetic Resonance Imaging Evaluation of Endometrial Carcinoma: A Retrospective Case Series *GRS Journal of Multidisciplinary Research and Studies*, Vol-3 (Iss-5).1-8.

### Introduction

Endometrial carcinoma is the most common gynaecologic malignancy in developed countries and ranks among the top five cancers affecting women globally. In India, it constitutes approximately 4–5% of all female cancers and is increasingly encountered at tertiary care centres due to rising incidence of obesity, diabetes mellitus and late menopause—all established risk factors. The hallmark presenting symptom is postmenopausal uterine bleeding, which, when investigated promptly, often allows diagnosis at an early stage.

Treatment planning in endometrial carcinoma is primarily guided by the International Federation of Gynaecology and Obstetrics (FIGO) staging system, which was revised in 2023. The critical parameters influencing prognosis include the depth of myometrial invasion, cervical stromal involvement, parametrial extension and lymph node status. Surgical staging by total hysterectomy with bilateral salpingo-oophorectomy (TH+BSO) and pelvic/para-aortic lymph node dissection remains the gold standard; however, accurate preoperative imaging is essential to stratify patients for surgery, sentinel node mapping and adjuvant chemoradiation.

MRI with its excellent soft-tissue contrast is the preferred preoperative imaging modality for endometrial carcinoma.

Multiplanar T2-weighted sequences delineate the junctional zone and assess myometrial invasion, while diffusion-weighted imaging (DWI) with apparent diffusion coefficient (ADC) mapping and dynamic contrast-enhanced (DCE) sequences further improve accuracy in tumour detection, depth of invasion and nodal characterisation. Previous meta-analyses have reported MRI sensitivity of 87–93% and specificity of 84–96% for detecting deep myometrial invasion (Kinkel et al., 1999; Frei et al., 2000).

Despite its established role, there are limited published data from government tertiary care institutions in central India. The present study aims to analyse the MRI findings, describe their utility in FIGO staging and highlight representative cases from our institutional experience at IGGMCH Nagpur.

## Materials and Methods

### Study Design and Patient Selection

This was a retrospective observational study conducted in the Department of Radiodiagnosis, Indira Gandhi Government Medical College and Hospital (IGGMCH), Nagpur, Maharashtra, India over a period of five years from November 2020 to December 2025. Institutional ethics committee approval was obtained. Sixteen patients referred to the MRI suite with clinical, ultrasonographic or histopathological suspicion of endometrial carcinoma who underwent contrast-enhanced MRI of the pelvis were included. Patients with incomplete MRI examinations, contraindications to gadolinium or unavailable clinical records were excluded.

### MRI Protocol

All examinations were performed on a 3 Tesla MR scanner (Siemens as available). Patients were instructed to fast for 4 hours and received antiperistaltic agents where appropriate. The standard imaging protocol comprised:

- T2-weighted fast spin-echo sequences in axial, sagittal and coronal planes (slice thickness 3–4 mm)
- T1-weighted sequences in the axial plane
- Short-Tau Inversion Recovery (STIR) sequences
- Diffusion-weighted imaging (DWI) with b-values of 0, 500 and 1000 s/mm<sup>2</sup> with corresponding ADC mapping
- Gradient echo (GRE) sequences for detection of haemorrhagic foci

- Dynamic contrast-enhanced (DCE) multiphase sequences following intravenous injection of gadolinium-based contrast agent (0.1 mmol/kg body weight)
- Abdomen screening sequences (in selected cases)

### Image Analysis

Images were reviewed on a dedicated PACS workstation by qualified radiology residents under the supervision of senior faculty. The following parameters were systematically evaluated for each case: (1) uterine size and position; (2) tumour location and dimensions; (3) signal characteristics on T1, T2, STIR and DWI sequences; (4) depth of myometrial invasion classified as superficial (<50%) or deep (≥50%) based on integrity of the junctional zone on T2WI; (5) cervical stromal involvement (loss of normal T2 hypointense stromal ring); (6) parametrial and adnexal extension; (7) involvement of urinary bladder, rectum or vagina; (8) pelvic and para-aortic lymph node status; and (9) distant metastases on abdominal screening. FIGO staging (2023 revision) was assigned based on the composite MRI findings in correlation with available histopathological data.

## Results

### Demographic and Clinical Profile

A total of 16 patients were included in the study. The age ranged from 35 to 65 years with a mean of 58 years. Postmenopausal bleeding was the predominant presenting symptom, noted in 14 of 16 patients (87.5%). One patient (35 years) presented with irregular premenopausal bleeding and was found to have histopathologically confirmed complex endometrial hyperplasia with atypia on prior curettage. Comorbidities included hypertension (n=3), type 2 diabetes mellitus (n=2) and hypothyroidism (n=1). Three patients had prior histopathological confirmation of endometrial carcinoma before MRI; in the remaining 13, MRI was performed for initial staging or diagnostic workup.

### MRI Findings – Aggregate Data

An endometrial mass or abnormal endometrial signal was detected in all 16 patients on MRI. The major findings are summarised in Table 1.

*Table 1: Summary of MRI findings in 16 patients with endometrial carcinoma*

MRI Finding	Number of Cases (n=16)	Percentage (%)
Endometrial mass detected	16	100
Superficial myometrial invasion (<50%)	6	37.5
Deep myometrial invasion (≥50%)	5	31.25
No myometrial invasion	5	31.25
Cervical stromal involvement	5	31.25
Parametrial extension	4	25.0
Pelvic/para-aortic lymphadenopathy	4	25.0
Distant metastases	2	12.5

## FIGO Staging Distribution

MRI-based FIGO staging (2023 classification) revealed a spectrum from early to advanced disease (Table 2). Five patients (31.25%) were staged as FIGO IA, three (18.75%) as FIGO IB, four (25%) as FIGO II, two (12.5%) as FIGO IIIB/IIIC and two (12.5%) as FIGO IVB.

**Table 2: MRI-based FIGO staging distribution (n=16).**

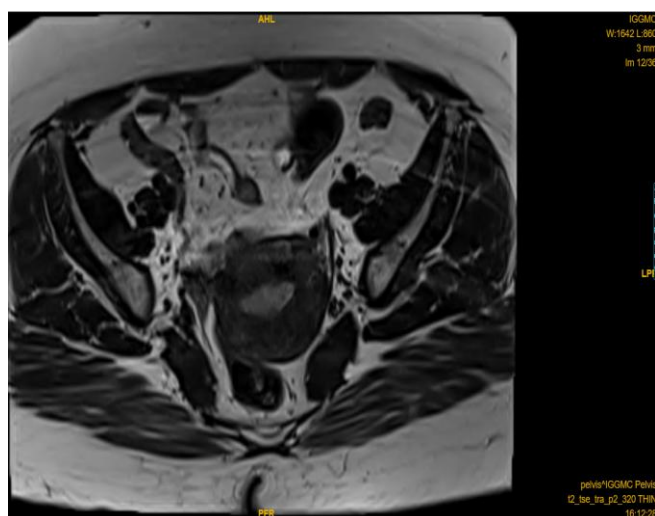
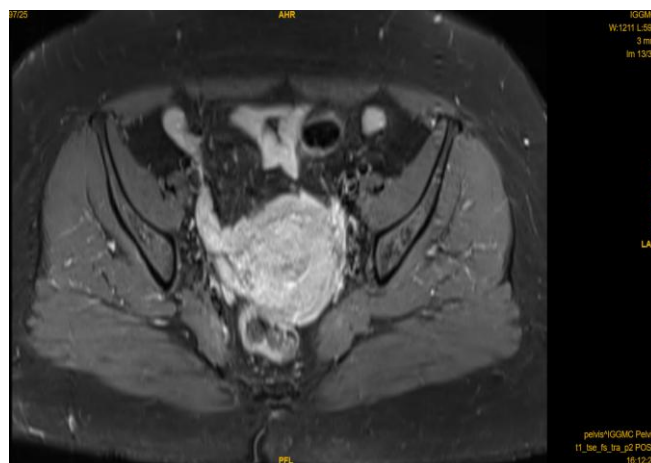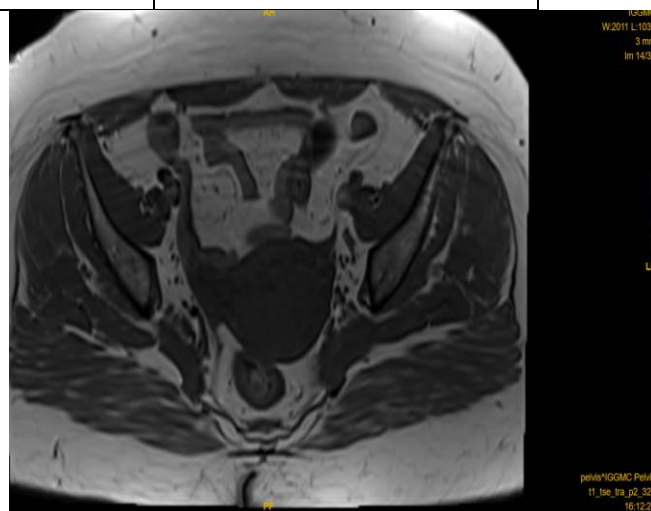
FIGO Stage	Number of Cases	Percentage (%)
Stage IA (Tumour confined to endometrium/½ myometrium)	5	31.25
Stage IB (Invasion $\geq$ 50% myometrium)	3	18.75
Stage II (Cervical stromal involvement)	4	25.0
Stage IIIB/IIIC (Parametrial/nodal spread)	2	12.5
Stage IVB (Distant metastasis)	2	12.5
<b>Total</b>	<b>16</b>	<b>100</b>

### Representative Case Descriptions

Five representative cases illustrating the spectrum of MRI findings across different stages are described below.

#### Case 1: FIGO Stage IA – Endometrial Adenocarcinoma

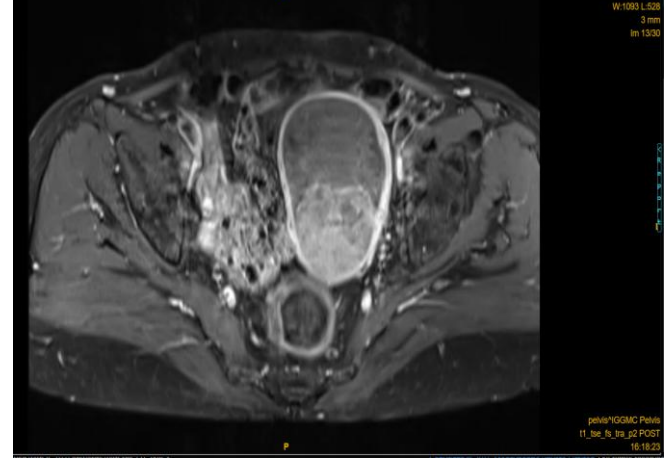
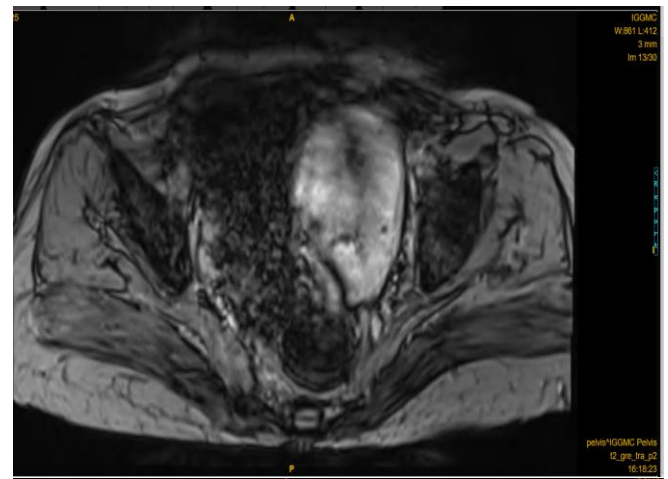
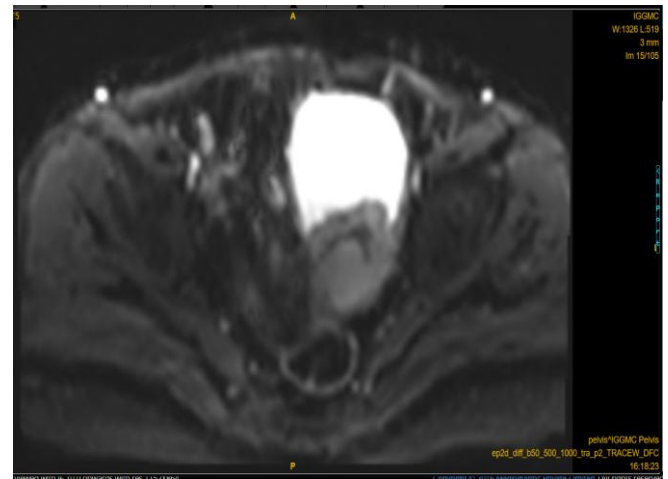
A 54-year-old postmenopausal woman (menopause 8 years prior, P4L2A2) presented with bleeding per vaginum for 2 months. She was a known case of type 2 diabetes mellitus and hypothyroidism. Prior ultrasonography suggested endometrial hyperplasia and subsequent histopathological examination (HPE) confirmed endometrial adenocarcinoma. MRI pelvis with abdomen screening (contrast-enhanced) revealed a bulky, retroverted and anteфлекted uterus measuring 5.1×5.0×7.8 cm. The endometrium appeared thickened (13 mm), mildly hyperintense on T2WI with mild delayed heterogeneous post-contrast enhancement. The junctional zone showed uniform thickness with normal signal intensity and there was no evidence of myometrial invasion. The cervix, parametrium, adnexae, vagina and pelvic lymph nodes were normal. Abdomen screening revealed a small cortical cyst in the upper pole of the left kidney and a mildly prominent common bile duct (6.6 mm). Impression: Endometrial carcinoma, FIGO Stage IA.



#### Case 2: FIGO Stage IIIB – Lower Uterine Segment Mass with Parametrial Involvement

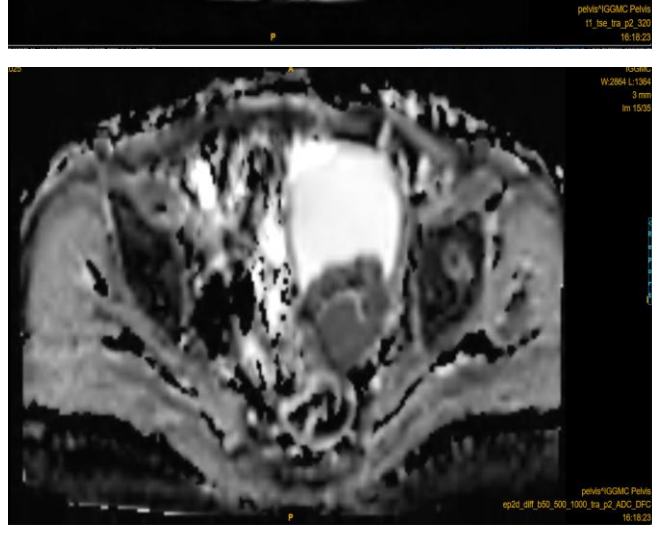
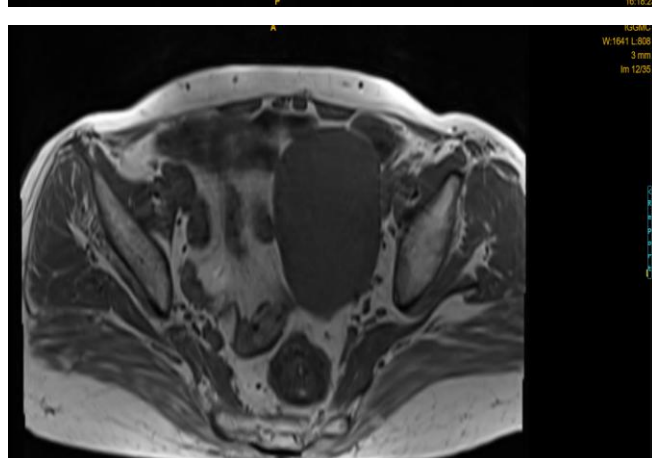
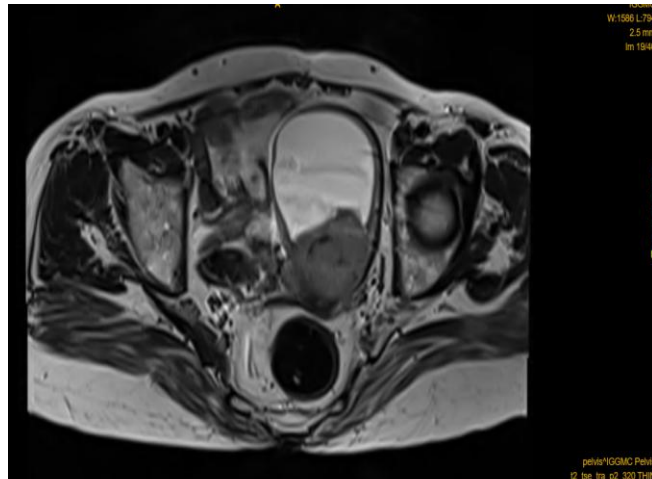
A 65-year-old postmenopausal woman (menopause 20 years prior) with known hypertension on Atenolol presented with watery vaginal discharge and spotting for 1–2 months. Prior non-contrast CT of the abdomen had revealed a mild endocervical and endometrial collection with a calcified focus in the posterior uterine wall. MRI pelvis with contrast demonstrated a bulky anteverted uterus (7.9×5.8 cm). An ill-defined lesion measuring

4.5×4.6×5.0 cm was identified in the lower uterine segment, closely abutting the internal os, causing significant narrowing of the proximal endocervical canal with resultant endometrial collection of approximately 75 mL. The lesion was isointense on T1WI, hyperintense on T2WI and STIR, with areas of diffusion restriction on DWI and foci of blooming on GRE consistent with haemorrhage. Dynamic contrast study showed early enhancement similar to adjacent myometrium with heterogeneous hypoenhancement on delayed sequences. There was loss of the normal T2 hypointense myometrial rim in the left posterolateral aspect of the lower uterine segment with mild adjacent parametrial fat stranding, indicative of parametrial extension. Fat planes with the urinary bladder and rectum were maintained. No significant pelvic or para-aortic lymphadenopathy was detected. Impression: Endometrial carcinoma, FIGO Stage IIIB.

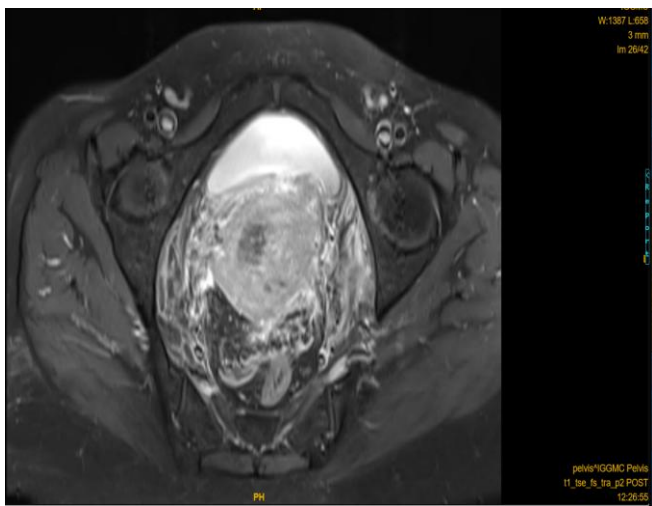
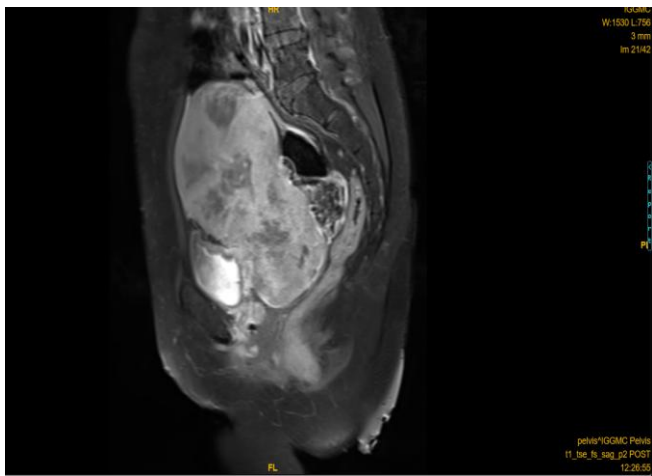
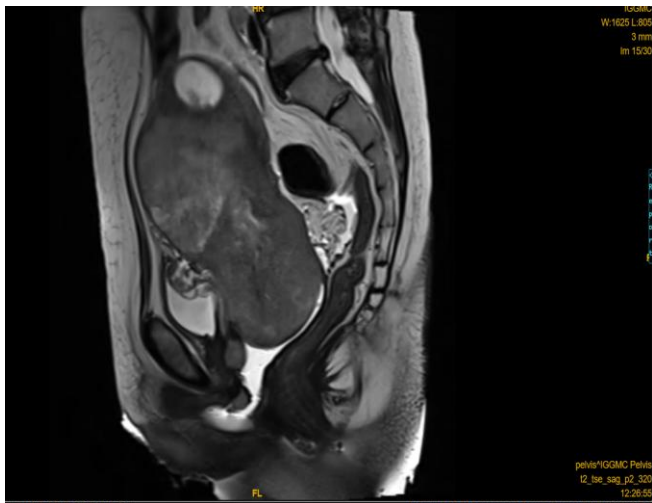
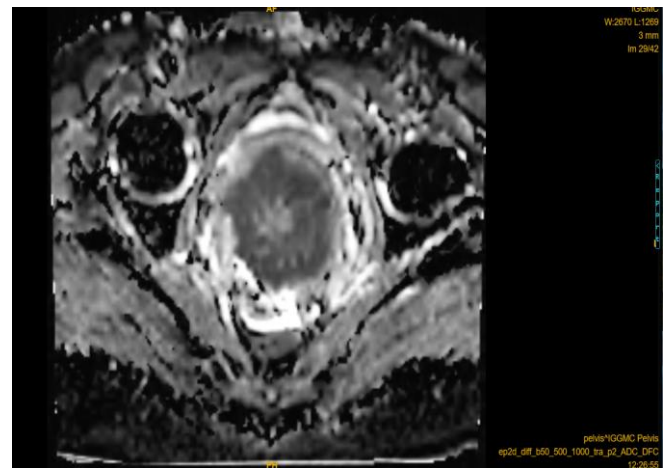
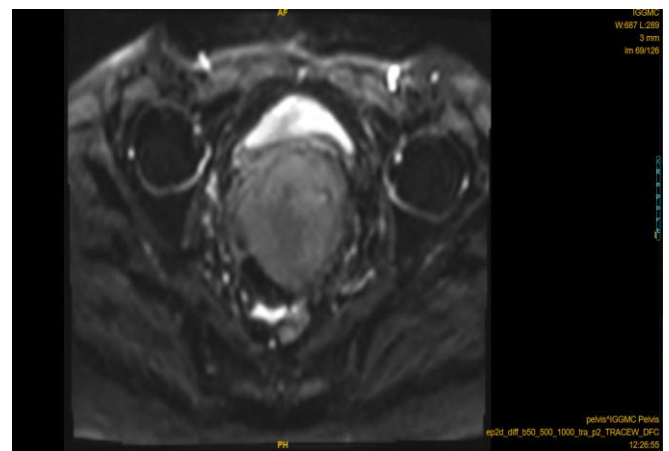
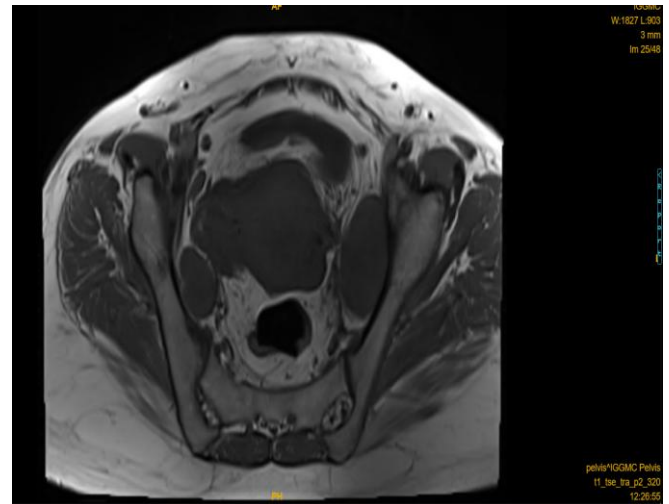
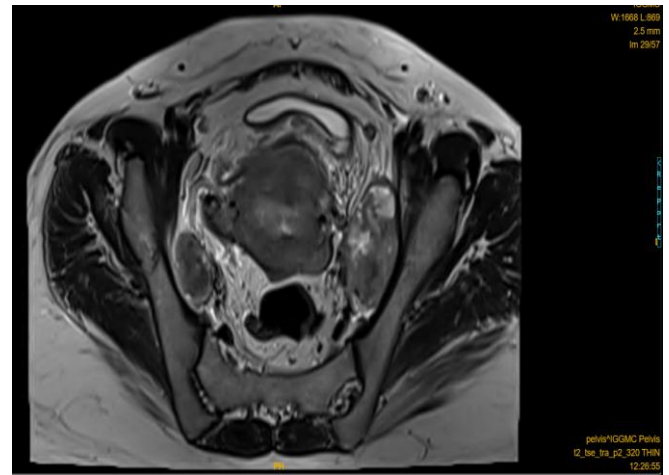


### Case 3: FIGO Stage IVB – Advanced Endometrial Carcinoma with Bladder and Nodal Involvement

A 46-year-old woman presented with postmenopausal bleeding and abdominal pain for 1 year, foul-smelling white discharge and dysuria. Prior ultrasonography suggested a neoplastic aetiology (differential: carcinoma cervix vs. carcinoma endometrium). MRI pelvis with abdomen screening revealed a retroverted bulky uterus (7.3×9.3 cm) with an ill-defined circumferential mass measuring 7.7×8.5×11.3 cm involving the endomyometrial junction predominantly in the lower two-thirds of the uterus, extending inferiorly into the cervix. The lesion was isointense on T1WI, hyperintense on T2WI/STIR with areas of diffusion restriction and haemorrhagic foci on GRE. Dynamic contrast imaging showed early hypoenhancement relative to myometrium with heterogeneous delayed enhancement. There was bilateral parametrial fat stranding with loss of the normal T2 hypointense

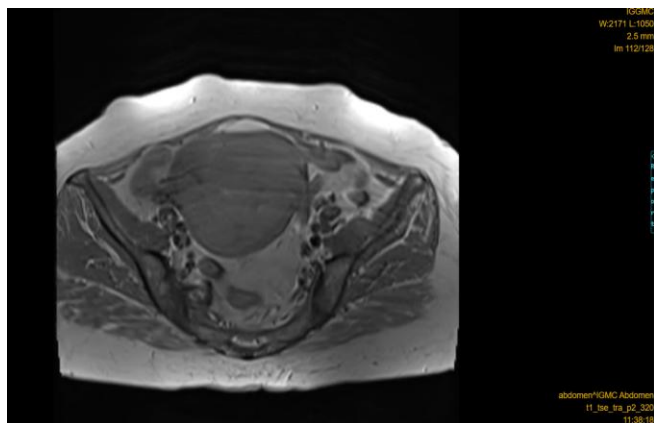
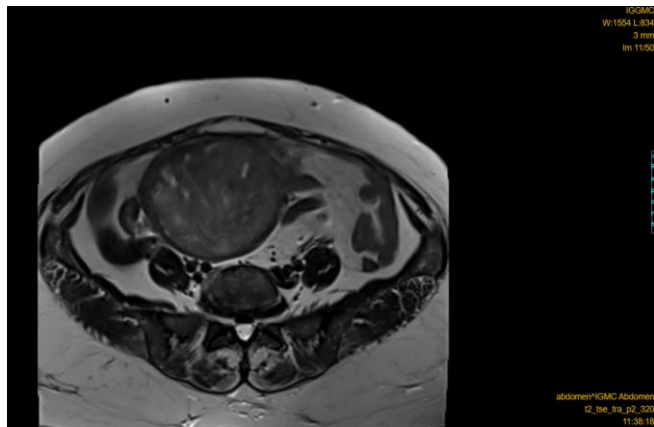
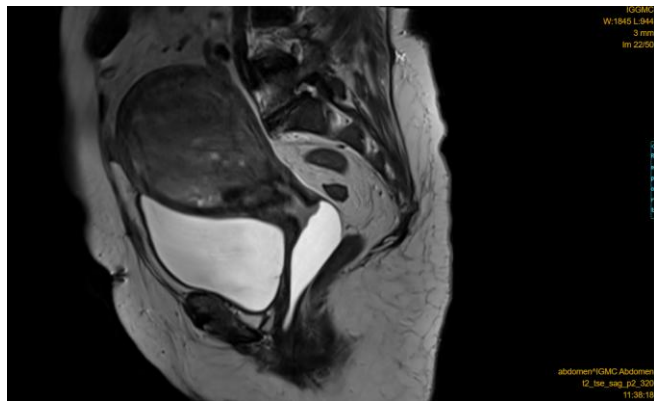
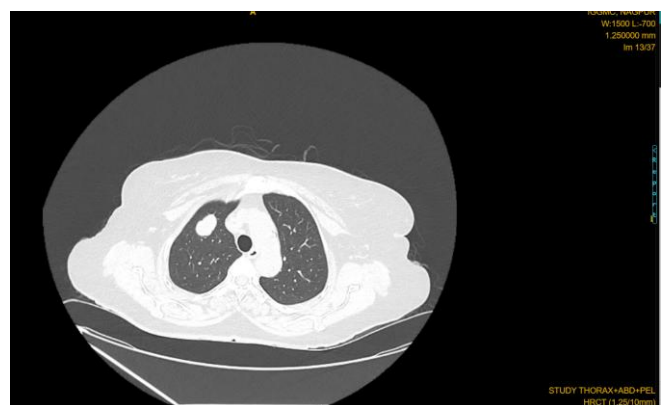
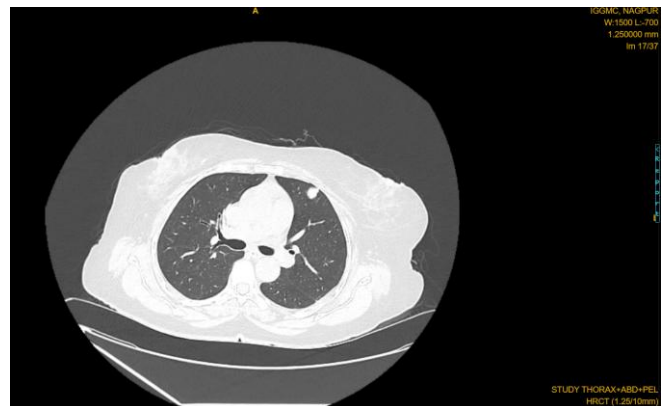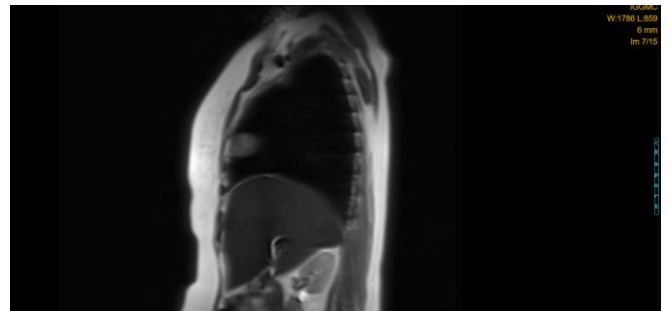
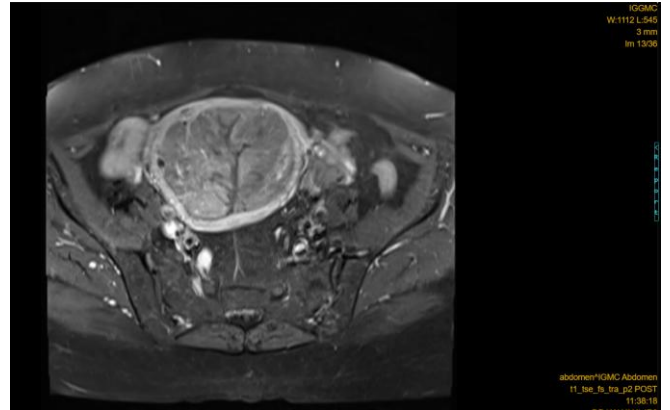
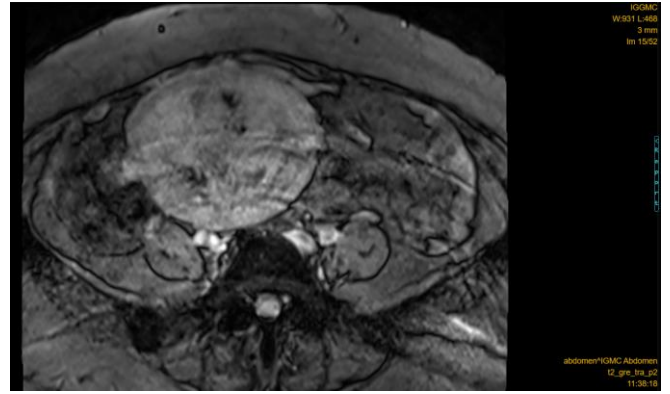


cervical ring posterolaterally. Anteriorly, focal loss of fat planes with the posterior wall of the urinary bladder was consistent with bladder wall invasion. Posteriorly, the lesion extended into the adjacent mesorectal fascia with suspicious focal loss of fat planes with the rectum. Multiple enlarged necrotic lymph nodes were identified in the bilateral obturator, inguinal, external iliac and para-aortic regions, the largest measuring 5.4×3.5 cm along the left external iliac vessel; the left ovary was not seen separately from this nodal mass. Heterogeneously enhancing deposits were noted in the anterior vaginal wall, perineum and left ischium (bone marrow signal alteration). Abdomen screening showed borderline hepatomegaly (15.5 cm); other solid organs were unremarkable. Impression: Endometrial carcinoma, FIGO Stage IVB.



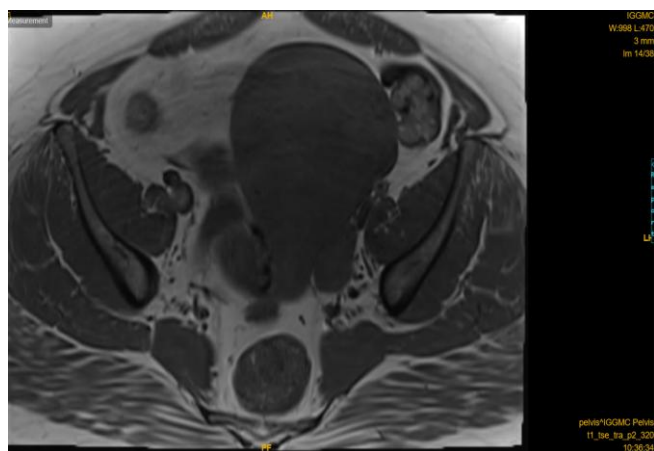
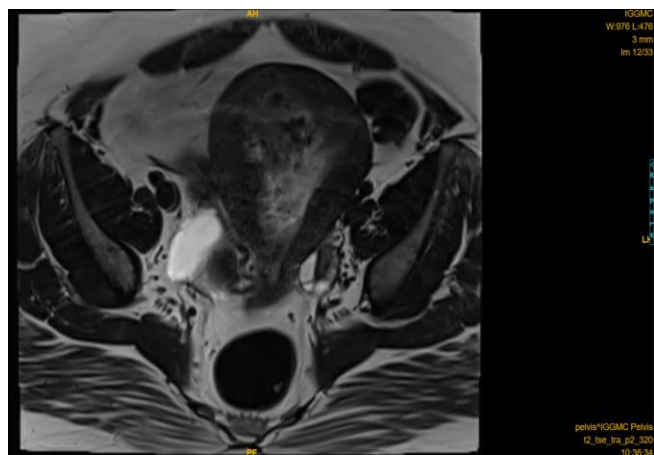
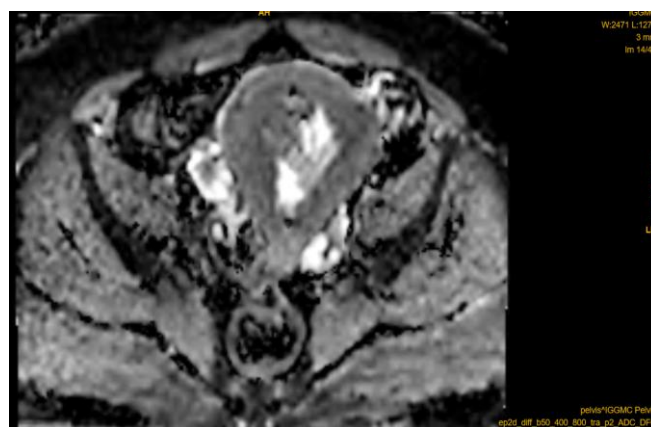
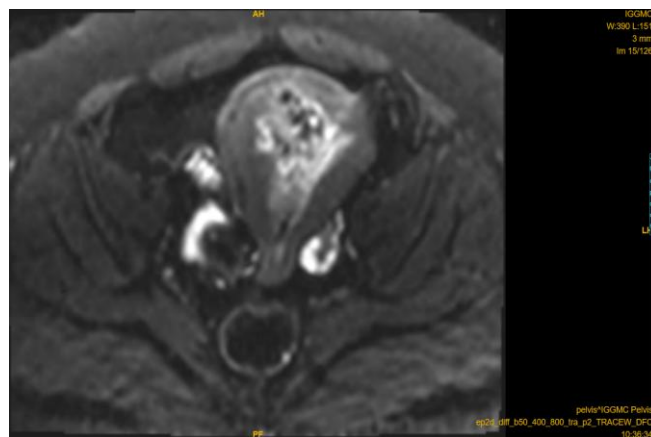
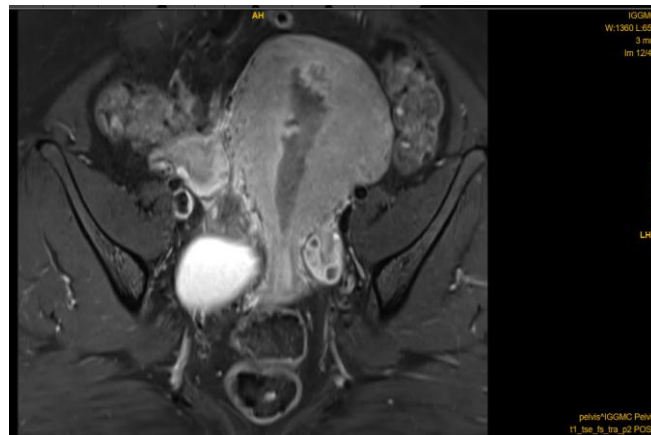## Case 4: FIGO Stage IVB – Clear Cell Carcinoma with Nodal and Pulmonary Metastases

A 65-year-old postmenopausal woman with histopathologically confirmed clear cell carcinoma of the endometrium presented with postmenopausal bleeding for 8 months. MRI pelvis demonstrated a large heterogeneously enhancing mass filling the endometrial cavity, measuring 10.9×6.8×8.7 cm (CC×AP×TR), extending into the upper two-thirds of the endocervical canal. The lesion was isointense on T1WI, iso- to hypointense on T2WI with heterogeneous post-contrast enhancement and diffusion restriction; internal foci of blooming on GRE indicated haemorrhage and necrosis. No definite myometrial invasion was identified. Bilateral enlarged external iliac lymph nodes were present (right: 2.5×1.5 cm; left: 2.4×1.5 cm), consistent with locoregional nodal metastasis. Abdomen screening revealed sludge in the gallbladder and a well-defined lesion in the lung measuring 1.2×1.2 cm, consistent with pulmonary metastasis (subsequently confirmed on CT chest). Impression: Clear cell carcinoma of endometrium with bilateral external iliac lymphadenopathy and pulmonary metastasis, FIGO Stage IVB.



## Case 5: Complex Hyperplasia with Atypia – Early Carcinoma Not Excluded (Indeterminate)

A 35-year-old premenopausal woman presented with irregular menstrual bleeding for 1 year. Histopathological examination following dilatation and curettage (D&C) confirmed complex endometrial hyperplasia with atypia. MRI pelvis with contrast revealed a bulky anteverted uterus measuring 7.6×8.7×11.7 cm. The endometrium was thickened (11 mm maximum) and irregular with a mild endometrial collection (13 mm) containing blood products (blooming on GRE). The endo-myometrial junction was indistinct with linear T2-hyperintense striations and tiny subendometrial cysts in the anterior and posterior myometrium, raising the possibility of adenomyosis. An ill-defined lesion measuring 2.8×2.9×4.2 cm was identified in the upper two-thirds of the uterus (fundic region), involving the endometrium and extending into the adjacent myometrium to a depth exceeding 50%. There was focal significant myometrial thinning at the right lateral fundal aspect. The lesion was isointense on T1WI, heterogeneously hyperintense on T2WI and showed enhancement similar to adjacent myometrium; no significant diffusion restriction was demonstrated. Bilateral ovaries showed multiple small peripherally arranged follicles (right ovarian volume 9 mL, left 8.6 mL) consistent with polycystic ovarian morphology. Subcentimetric enhancing lymph nodes were noted along bilateral iliac vessels (largest 8.2 mm in short axis, left external iliac). Impression: Imaging findings likely represent post-curettage changes and adenomyosis; however, early endometrial carcinoma cannot be excluded. Close follow-up and repeat HPE/MRI recommended.



## Discussion

The present study highlights the diverse MRI spectrum of endometrial carcinoma encountered at a tertiary government hospital in central India. The mean age of 58 years and predominance of postmenopausal bleeding as the presenting symptom in our cohort are consistent with published literature. However, the presence of a 35-year-old with complex hyperplasia with atypia and myometrial extension underscores the need for vigilance in premenopausal women with abnormal uterine bleeding.

Myometrial invasion is the single most important prognostic parameter in endometrial carcinoma, as it determines lymph node risk and thereby the extent of surgical staging. In our series, deep myometrial invasion ( $\geq 50\%$ ) was identified in 31.25% of patients. T2-weighted imaging allows assessment of junctional zone integrity; disruption or non-visualisation of the T2 hypointense junctional zone is the primary indicator of myometrial invasion. DWI further improves delineation by exploiting differential diffusion restriction between tumour and normal myometrium.

Post-contrast DCE sequences, particularly the early arterial phase, accentuate the contrast between enhancing myometrium and relatively hypoenhancing tumour, improving accuracy in equivocal cases—a finding consistent with the meta-analysis by Frei et al. which reported a sensitivity of 84% and specificity of 91% for contrast-enhanced MRI in predicting deep myometrial invasion.

Cervical stromal involvement (Stage II disease) was identified in 31.25% of our patients. MRI reliably differentiates endocervical extension (which does not upstage disease under FIGO 2023 guidelines) from true cervical stromal invasion, the latter evidenced by disruption of the T2 hypointense stromal ring. This distinction is critical as cervical stromal involvement mandates modified radical hysterectomy rather than simple hysterectomy. In our series, Case 2 exemplified Stage IIIB disease with an epicentre in the lower uterine segment extending to the internal os with parametrial fat stranding—a subtle finding that underscores the need for careful evaluation of the parametrial fat on sagittal T2WI and axial high-resolution sequences.

Advanced Stage IVB disease was recorded in two of our patients (12.5%), both of whom had histological subtypes associated with poor prognosis. Case 3 represented a massive tumour with bladder wall invasion, extensive nodal disease including bone marrow involvement and metastatic deposits in the vagina and perineum, consistent with FIGO IVB. Case 4 was a histopathologically confirmed clear cell carcinoma—a Type II endometrial cancer characterised by high-grade histology, aggressive behaviour and a propensity for early lymphatic and haematogenous spread. Despite the absence of myometrial invasion on MRI, bilateral external iliac nodal metastases and a pulmonary lesion confirmed Stage IVB disease, illustrating that nodal and distant spread can occur even without deep myometrial invasion in high-grade tumours.

The indeterminate case (Case 5) merits particular mention. In premenopausal women following endometrial curettage, the post-procedural endometrial disruption, haemorrhage and associated adenomyosis can closely mimic early endometrial carcinoma on MRI. The absence of diffusion restriction and the enhancement pattern similar to myometrium in this case favoured post-procedural changes; however, the depth of myometrial extension exceeding 50% in the fundal region warranted cautious interpretation and clinical follow-up. This scenario highlights the inherent limitations of MRI in the immediate post-D&C period and the importance of a minimum interval of 4–6 weeks between curettage and staging MRI.

The FIGO 2023 revised staging system introduced molecular subgrouping (POLE-mutated, mismatch repair-deficient, p53-abnormal and NSMP) that influences adjuvant therapy decisions. While our study is based on imaging and conventional histopathology, future studies from our institution will integrate molecular biomarkers to provide a comprehensive prognostic profile.

A limitation of this study is its retrospective nature and the absence of formal surgical-pathological staging correlation for all 16 cases. Additionally, all MRI examinations were not performed by the same operator, introducing potential inter-observer variability. Prospective studies with larger sample sizes and systematic surgical correlation are warranted.

## Conclusion

MRI is an indispensable preoperative imaging modality for endometrial carcinoma. It accurately evaluates the depth of

myometrial invasion, cervical stromal involvement, parametrial extension and extrauterine spread, thereby enabling precise FIGO staging that directly influences surgical planning and adjuvant therapy. The combination of T2-weighted imaging, DWI and dynamic contrast-enhanced sequences maximises diagnostic accuracy. Our institutional experience across a diverse disease spectrum – from incidental early-stage disease to bulky advanced carcinoma with distant metastases – corroborates the established role of MRI as the imaging modality of choice for preoperative staging of endometrial carcinoma.

## Declarations

**Conflict of Interest:** The authors declare no conflicts of interest.

**Funding:** No funding was received for this study.

**Ethical Approval:** Institutional ethics committee approval was obtained. Patient identifiers have been anonymised for publication purposes.

**Author Contributions:** BS and AD designed the study and supervised data collection and manuscript review. C and S performed data extraction, MRI evaluation and drafted the manuscript. All authors reviewed and approved the final manuscript.

## References

1. Hricak H, Stern JL, Fisher MR, Shapeero LG, Winkler ML, Lacey CG. Endometrial carcinoma staging by MR imaging. *Radiology*. 1987; 162(2):297–305.
2. Kinkel K, Kaji Y, Yu KK, Segal MR, Lu Y, Powell CB, Hricak H. Radiologic staging in patients with endometrial cancer: a meta-analysis. *Radiology*. 1999; 212(3):711–718.
3. Frei KA, Kinkel K, Bonel HM, Lu Y, Zaloudek C, Hricak H. Prediction of deep myometrial invasion in patients with endometrial cancer: clinical utility of contrast-enhanced MR imaging – a meta-analysis and Bayesian analysis. *Radiology*. 2000;216(2):444–449.
4. Sala E, Crawford R, Senior E, Shaw A, Dixon AK, Woolas R, et al. Added value of dynamic contrast-enhanced magnetic resonance imaging in predicting advanced stage disease in patients with endometrial carcinoma. *J Magn Reson Imaging*. 2009;29(2):321–329.
5. Nougaret S, Horta M, Sala E, Lakhman Y, Thomassin-Naggara I, Kido A, et al. Endometrial cancer MRI staging: updated guidelines of the European Society of Urogenital Radiology. *Eur Radiol*. 2019;29(2):792–805.
6. Amant F, Mirza MR, Koskas M, Creutzberg CL. Cancer of the corpus uteri. *Int J Gynaecol Obstet*. 2018;143(Suppl 2):37–50.
7. Colombo N, Creutzberg C, Amant F, Bosse T, González-Martín A, Ledermann J, et al. ESMO–ESGO–ESTRO consensus conference on endometrial cancer: diagnosis, treatment and follow-up. *Ann Oncol*. 2016;27(1):16–41.
8. Ueno Y, Forghani B, Forghani R, Dohan A, Zeng XZ, Chamadol N, et al. Endometrial carcinoma: MR imaging-based texture model for preoperative risk stratification – a preliminary analysis. *Radiology*. 2017; 284(3):748–757.